

What Are Dermatophytes?

- **Dermatophytes** are fungi that are most commonly found on the skin and hair of animals and people. Skin infection caused by dermatophytes is referred to as **ringworm, tinea, dermatophytosis** or **dermatomycosis**.
- Different dermatophytes are more common in certain species, such as *Microsporum canis* and *Trichophyton mentagrophytes* in dogs and cats.
- Dermatophytes that are adapted to humans (e.g. *T. rubrum*, the cause of athlete's foot) do not normally infect animals, but can contaminate their fur.
- Dermatophytes, specifically *M. canis*, are very **commonly found on cats**,
 - Signs of infection in animals are not always apparent.
 - **Cats** are considered the **primary zoonotic source of dermatomycosis** in humans.
 - Dermatomycosis is the most commonly reported zoonotic disease in people who work with cattle.
- Dermatomycosis is normally limited to skin infections, but in high-risk individuals (e.g. very young, elderly or immunocompromised) the infection can spread, resulting in much more severe systemic illness.



How Common Is Ringworm?


Humans



- Ringworm occurs all over the world, but in general it is not reportable so no one knows exactly how common it is. Many mild cases likely go undiagnosed.
- Ringworm from animals may account for 20-50% of fungal skin infections in humans. One study showed that 50% of people who had contact with infected cats developed infection with *M. canis*. Infection was more common in children than adults. In general, the very **young**, very **old**, or **immunocompromised** are more likely to be infected.
- Transmission from **rodents** can occur through contact with shed hair and skin in the environment, or indirectly via dogs and cats that hunt infected rodents and become infected or contaminated themselves.
- There may be some **genetic predisposition** to chronic ringworm in humans, and possibly cats, who have a certain type (antibody-based) of immune response to the fungi.

Animals


- The percentage of **dogs and cats suspected of having ringworm** that actually test positive for the fungus varies widely, from 14-92%. From 3-30% of **normal animals** may be positive. The percentage is consistently **higher in cats**.
- Ringworm may be less common in cats that do not have contact with other cats. It is more commonly found in **stray cats** and those from **multi-cat facilities**.
- Ringworm is more common in **warm, humid** environments. **Crowding and close contact** increases the likelihood of transmission. Any type of **minor skin trauma** or **chronic moisture** also increases the likelihood of infection.
- **Long-haired animals** may be predisposed to ringworm, as hair mats can interfere with normal grooming and provide an ideal environment for fungal growth on the underlying skin.
- **Excessive bathing or grooming** may also predispose animals to infection by increasing the hydration of the skin and removing the natural oils and proteins on the skin that help prevent fungus from growing.



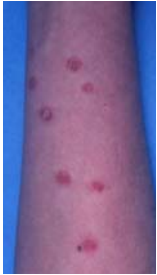How Is Ringworm Spread?

The natural habitat of dermatophytes is the skin of humans and animals. The fungi grow around hair shafts and in the superficial layers of skin, where they form **infective arthrospores**. Large numbers of these arthrospores are present in shed skin cells and hairs, and may remain infectious for months or even years in the environment. The arthrospores usually only start to grow again when exposed to warm, humid conditions, such as when they come in contact with broken or macerated skin. **Arthrospores cannot penetrate normal, intact, dry skin**,

- People and animals can be infected by **direct** skin-to-skin contact with another infected person or animal, or by **indirect** contact through things like contaminated clothing, blankets or hairbrushes.
- Arthrospores can also be spread like dust in **air currents**, or by **vectors** like fleas.
- Zoonotic dermatophytes spread more easily between animals and people than between people alone.
- Animals are occasionally infected with environmental fungi such as *M. gypseum* from digging in **rich soil**.
- Infection with *Trichophyton* spp. is commonly associated with direct or indirect contact with **rodents**.




How Do I Know If My Pet Or I Have Ringworm?



Humans: Like many fungi, dermatophytes grow best in warm, moist environments, but they can grow almost anywhere on the body. The incubation period for infection is 1-2 weeks. In children 4-11 years old, the disease most commonly occurs on the scalp. The infection can be, but is not necessarily, quite itchy. A classic “ringworm” skin lesion tends to spread out from one point on the skin, causing hair loss as it progresses, resulting in a **bald patch**. The outside (most active) edge of the infection often appears as a **red ring**, from which the condition gets its name (photo left: ringworm lesions on a person’s arm (credit A. Yu)). Fungi that are adapted to humans tend to cause less pronounced signs of infection. In HIV/AIDS patients, lesions from *T. mentagrophytes* and *M. canis* infection may spread over the skin all over the body.

Animals: Not every animal that is infected with ringworm develops signs of infection. It has been estimated that ~90% of cats carrying dermatophytes **do not show any clinical signs**. The incubation period is generally 1-3 weeks. Particularly in cats, ringworm can mimic almost any skin condition. Classic ringworm lesions (as described above) are more common in dogs than cats. Cats most commonly develop lesions on their **face and paws** (see picture right (credit A. Yu)) and may be anywhere from intensely itchy to not itchy at all.



Mice and guinea pigs are typically affected by *T. mentagrophytes*, but may not have any apparent lesions. Lesions in **horses** can range from dry, bald, thickened, scaly skin and brittle hair, to oozing lesions that cause hair to stick together and are extremely itchy. **Calves** are affected more frequently than mature cattle, and typically develop grey-white, dry lesions on the face and neck that then scab and leave a bald area. **Sheep** are not commonly affected by ringworm, but infection can occur, particularly on the head and face, and is easily spread between sheep by sheering implements and close contact after sheering. The fungi that cause ringworm in **swine and chickens** are rarely transmitted to humans, but a few cases have been reported.

How Is Ringworm Diagnosed?

Approximately half of *M. canis* strains will fluoresce blue-green under a special ultraviolet light called a **Wood’s lamp**. However, other debris in an animal’s hair coat may fluoresce as well, and other species of dermatophytes do not fluoresce, so this test is not useful by itself in most cases. Sometimes the fungus can be seen on hair shafts when examined under a **microscope**, but it is easy to confuse other debris and structures for dermatophytes, or to miss the infected hairs altogether. The best way to diagnose ringworm is to **culture** the fungus from the infected individual. In animals, one of the best ways to do this is to comb over all the fur and skin with a new **toothbrush**, and then try to grow dermatophytes from the toothbrush. Fungal culture takes much longer than bacterial culture – instead of days, it may take up to three weeks to grow some dermatophytes.




Because cats so often carry dermatophytes even when they look healthy, a positive fungal culture from a cat with skin disease does not rule out other causes, so your veterinarian may still recommend other tests as well.


How Is Ringworm Treated?

Most healthy individuals will eventually eliminate a ringworm infection even if no specific treatment is given, but this may take several months (e.g. 60-100 days in cats). Nonetheless, any animal (or person) found to be carrying a zoonotic dermatophyte should be treated in order to decrease the risk of spread to other animals and people.

Humans: Most cases of ringworm can be treated with either oral medication or topical ointments. The keys are that treatment must be continued for a long time (at least 2-3 weeks) and reinfection must be avoided.

Animals: It is important to treat infected animals both **systemically** (usually with oral medication) and **topically** (e.g. dips, shampoos, sprays) to help reduce ongoing contamination of the environment; the **combination** can help eliminated the infection more rapidly than either type of therapy alone. Unfortunately, some anti-fungal medications can be quite expensive, especially for large dogs. Topical treatment must be applied to the animal’s **whole body** – just treating the areas where the infection is obvious is ineffective. **Body clipping**, particularly long-haired animals, is recommended, but may not be necessary for shorthaired animals with only a few small lesions. **Cleaning the animal’s environment at the same time is essential** to effective treatment. Treatment should be continued until 2-3 recheck cultures (done every week or every other week starting at four weeks) are negative.





- Treatment **failures or relapses** are often due to not treating **thoroughly enough**, not treating for **long enough**, failure to **decontaminate the environment**, **underlying illness** or **incorrect diagnosis**.
- There are vaccines to prevent ringworm in livestock, but at the moment there is **no ringworm vaccine** available for companion animals.

What Do I Do If My Pet Has (Or May Have) Ringworm?

Infected Animals: Animals with known or suspected ringworm infection should be confined to a separate, easy-to-clean room to prevent spread of the infection. Whether lesions are present or not, treatment with topical and oral medication is recommended. **An infected animal may have infective fungus on any or all areas of its fur/skin.**

Environment: Eliminating ringworm from a household can be difficult, because the fungi can be found anywhere that an infected animal (or person) sheds hair or skin cells. Recommendations for environmental disinfection are:

- Dust all surfaces and ledges with a **disposable dusting cloth** (e.g. Swiffer).
- All bedding, brushes, combs, rugs, cages, etc. should be **vacuumed** and **scrubbed** with hot water and detergent. This should be followed by application of an **effective disinfectant** (see below). It is best to discard any items that cannot be thoroughly disinfected.
 - Walls, floors, lamps, etc. should be scrubbed and cleaned in a similar manner.
 - Ideally use a **wet-dry vacuum** to remove any dirty water after cleaning.
 - Ensure sufficient **contact time** with disinfectant for all surfaces (e.g. at least 10 minutes for bleach).
 - Wear appropriate **protective clothing** (e.g. gloves, eyewear) and ensure the room is well **ventilated** during disinfection. Ideally place a fan by a window to blow air out of the room to the outdoors.
- Use a **disposable mop pad** to clean non-porous surfaces in high-traffic rooms.
- **Carpeted areas** may be impossible to effectively decontaminate. If possible, remove the carpet and either wash it in hot water and bleach, or discard it. Otherwise, frequent vacuuming with immediate disposal of the collection bag is necessary. However, **regular vacuuming may actually spread fungus** further around a room. To avoid this, use only vacuums equipped with a **HEPA filter**, **steam cleaning** or a **central vacuum unit**.
- **Vehicle interiors** should be decontaminated as much as possible in a similar manner.
- **Curtains** can be dry-cleaned at a professional cleaner.
- Clean all **heating vents**, and install a good-quality furnace filter. The filter should be changed according to the manufacturer's recommendations, and at the very end of the decontamination process. Ideally, do not keep infected animals in a room with a cold air return.
- Avoid blowing air from heavily contaminated rooms to other parts of the house. If fans are used to improve air circulation, they should be pointed to blow air outside.
- Use a **dehumidifier** to reduce the humidity in heavily contaminated rooms.



Mopping/vacuuming and dusting in heavily contaminated rooms should be done **daily**, and disinfection should be done at least **weekly**. In other rooms, cleaning and disinfection should be repeated at least once **every 4-6 weeks** (the more often, the better) until all affected animals and people have eliminated the fungal infection.




In **catteries**, additional recommendations for control of dermatomycosis include:

- Cats should be separated into clean and contaminated rooms/areas according to individual infection status.
- Use disposable garbage bags to cover clothes while treating infected cats or working in contaminated rooms.
- Wear designated footwear in areas housing infected cats.

Many **environmental disinfectants** labeled for use against ringworm are, in fact, not effective, because the fungi are usually found on small fragments of infected hairs, which may protect them from the actions of some disinfectants. Disinfectants that are effective against ringworm on infected hair and skin in the environment include:

- **Household bleach** (1:10 to 1:100 solution in water): Cheap and readily available.
- **Lime sulfur** (1:33 solution): Effective, but many people don't like the smell.
- **Enilconazole** (0.2% solution used as an environmental spray): Also used as a topical treatment for dogs and horses, this compound is approved for use in catteries, but technically not for household use.

Use of other products, including Virkon-S® (a detergent-peroxide based product) and Peroxigard® (an accelerated hydrogen peroxide product) have been recommended in some cases, but their efficacy in published studies varies.



How Can I Prevent The Spread of Ringworm?

Control and clean-up of ringworm after having one or more pets infected can be a major undertaking, and often requires weeks to months of diligent animal care and environmental disinfection. If ringworm can be identified early, lesions can potentially be kept covered and movement of affected animals can be restricted to reduce the extent and amount of environmental contamination.



- **Early identification of ringworm is key.** If your pet develops bald patches, particularly if they're itchy, it should be examined by your veterinarian as soon as possible.
- If you or anyone in your household develops an area of skin that appears infected (especially if it appears as a red "ring"), keep it covered with a piece of clothing or a bandage and see your doctor. Let the doctor know about any pets you have.
- Clean your pet's grooming supplies (e.g. brushes, combs) regularly.
- Always **wash your hands** after handling your pet, its bedding, toys and other articles.
- If you get a new pet (especially a cat) from an animal shelter, rescue group or pet store, a toothbrush culture of the hair coat should be performed as part of the animal's routine examination, particularly if there are any high-risk individuals (e.g. young children, elderly or individuals with a weakened immune system) in the household.

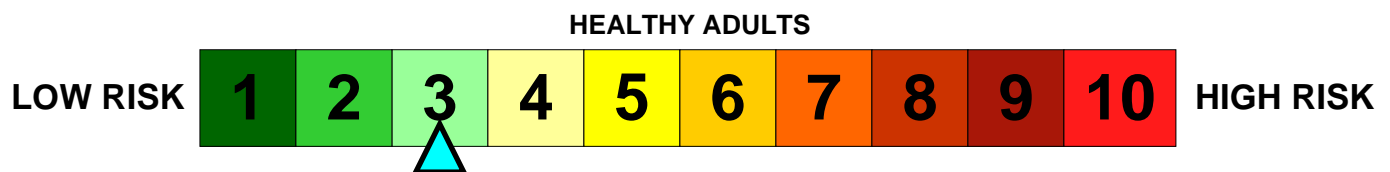
Therapy Animals

Guidelines have been developed to reduce the risk of pets involved in animal visitation programs acquiring or transmitting infectious diseases, as these animals may frequently come in contact with individuals with weakened immune systems. However, control of ringworm is not specifically considered in these guidelines. It is prudent to include a toothbrush culture with any regular examination (i.e. twice yearly) of cats involved in such a program, particularly if the animals are from a multi-cat household. The prevalence of dermatomycosis in clinically normal dogs is likely low enough that this is unnecessary for these animals.

If I Have Ringworm, Should I Test My Pets?

If a person is diagnosed with a ringworm infection involving a fungal species commonly found in animals (e.g. *M. canis*), then any pets should be examined by a veterinarian and a toothbrush culture performed. Because these fungi can be transmitted from animals to people and vice versa, a positive culture from a pet does not necessarily mean the animal was the source of infection, but all culture-positive animals should be treated to prevent ongoing contamination of the environment and reinfection of other household members and pets.

The zoonotic risk to the general population posed by ringworm in house pets such as dogs and cats is:



Individuals with compromised immune systems (e.g. HIV/AIDS, transplant and cancer patients) are more susceptible to many kinds of infections, including those which may be transmitted by pets. While these individuals are not advised to get rid of their pets, precautions should be taken to reduce the frequency of contacts that could result in pathogen transmission. **Infants and young children** (less than 5 years old) are more likely than adults to extensively handle animals if given the opportunity, more likely to touch their faces or mouths, and less likely to wash their hands after handling an animal. Children may "snuggle" with pets; this very close contact can increase the risk of disease transmission.

- Pets with abnormal skin lesions should be promptly examined by a veterinarian to determine the cause as soon as possible. High-risk individuals should avoid handling affected animals at least until the diagnosis is known.
- Keep all cuts and damaged skin covered to prevent contamination with pet hair and dander.
- Do not allow pets to sleep in the same bed as a high-risk individual.
- Thorough **hand hygiene** after touching any animal, as always, is very important.

For these groups, the zoonotic risk posed by ringworm in house pets such as dogs and cats is likely:

